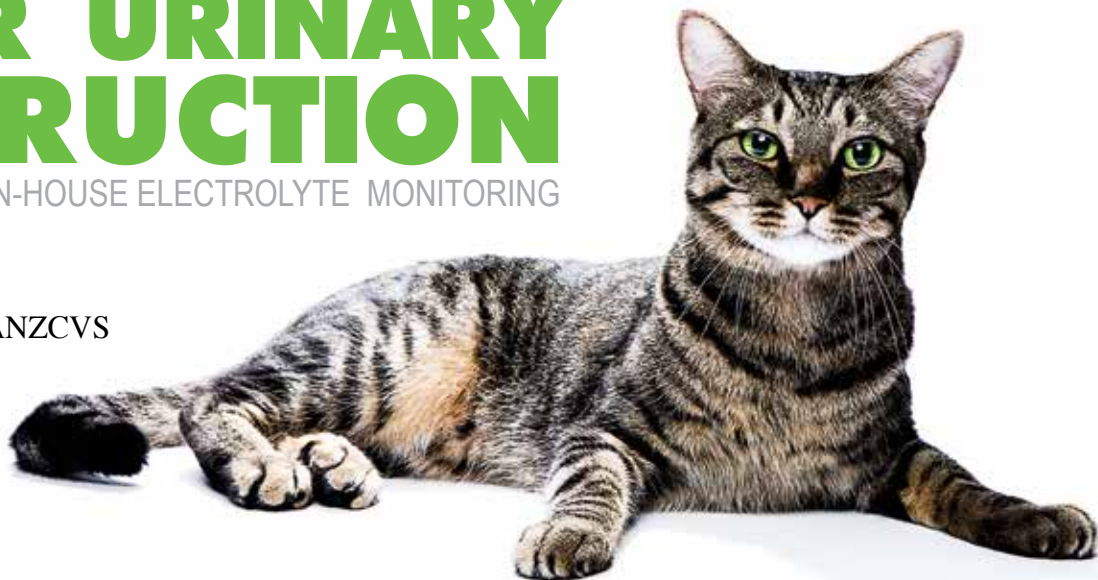

FELINE LOWER URINARY OBSTRUCTION

THE IMPORTANCE OF IN-HOUSE ELECTROLYTE MONITORING

Contributing Author:

Dr. Amy Pierce BVSc MANZCVS
Pet Vet Lower Hutt
Wellington, New Zealand



Terror, a 7 year old MN Domestic Short Hair cat presented in late February 2012 with inappetance and stranguria. On physical examination he was found to have caudal abdominal pain and a moderately full bladder. He was tachycardic (200bpm) and tachypnoeic (48bpm) as would be expected for a painful, stressed cat. He was bright, alert and responsive, had pink mucous membranes and a capillary refill time of 1 second. A temperature of 36.6°C was the only clue on initial physical examination that this cat was a lot sicker than he initially appeared.

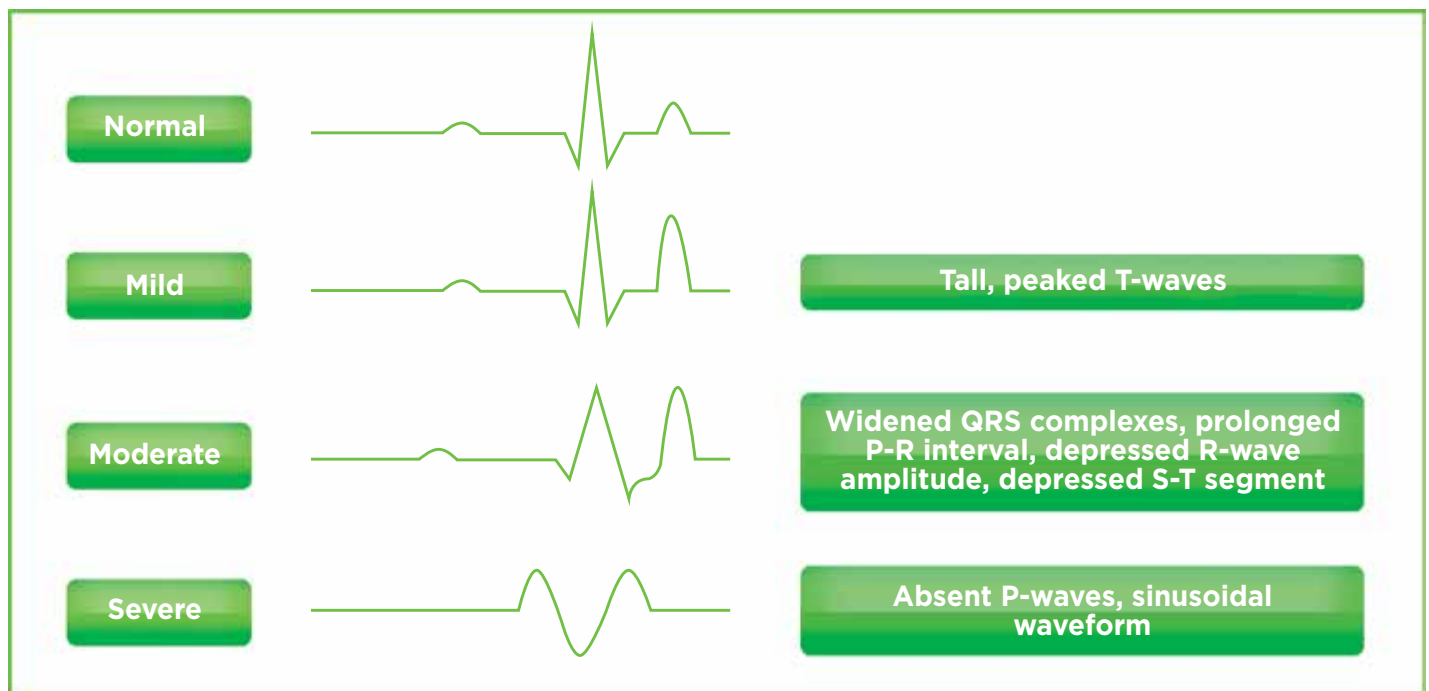
Terror was admitted to hospital for treatment of his lower urinary obstruction. An IV catheter was placed, pain relief given and blood was taken for a stat biochemistry panel and PCV/TP. This showed severe azotemia, hyperphosphataemia, hyperglycaemia and, possibly most concerning, severe hyperkalaemia (8.1mmol/L).

Fig. 1 Inital lab results

		VetScan Results		
Test Type	Units	Result	Normal Range	H/L
ALB	g/L	25	(22-44)	
ALP	U/L	16	(10-90)	
ALT	U/L	51	(20-100)	
AMY	U/L	475	(300-1100)	
TBIL	μmol/L	5	(2-10)	
BUN	mmol/L	57.2	(3.6-10.7)	H
Ca ²⁺	mmol/L	2.44	(2.00-2.95)	
CRE	μmol/L	948	(27-186)	H
GLU	mmol/L	14.6	(3.9-8.3)	H
Na ⁺	mmol/L	152	(142-168)	
K ⁺	mmol/L	8.1	(3.7-5.8)	H
TP	g/L	72	(54-82)	
GLOB	g/L	47	(15-57)	
PCV	%	58	(26-45)	H

Potassium is the major intracellular cation in the body. Its functions are multiple, but the most noticeable consequences of hyperkalaemia are related to prolongation of the depolarization and repolarization of excitable tissues. Bradycardia (or normal heart rate in a painful, stressed animal) is usually the most noticeable clinical sign. The classic ECG changes seen include tall 'peaked' T-waves, prolonged QRS complexes and P-R intervals and depressed R-wave amplitude and S-T segment. There is some variation as to at what serum potassium level these changes are first noted but generally they are seen at ~5.5-6.5mmol/L. As hyperkalaemia gets more severe (generally ~7-8mmol/L) progressive decreases in P-wave amplitude are seen, followed by atrial standstill. Muscle weakness may also be seen, generally when serum potassium levels exceed 7.5mmol/L.

Fig. 2. ECG changes seen with hyperkalaemia



Definitive treatment of hyperkalaemia requires identification and removal of the inciting cause- in this case urethral obstruction causing decreased urinary excretion. Short term measures may be used in patients with clinical signs of hyperkalaemia or severe elevations in serum potassium levels until more definitive management is possible. Calcium gluconate may have a cardioprotective effect via lowering cardiac muscle membrane potential but will not lower serum potassium levels. Glucose or dextrose will cause a spike in endogenous insulin release which causes translocation of potassium into the intracellular space, lowering serum levels. Administering additional regular insulin concurrently will enhance this effect but serum glucose levels must be closely monitored and additional glucose given post-administration.

Terror had a severe hyperkalaemia but was surprisingly not showing clinical signs of this. Despite his lack of clinical signs, the severity of his hyperkalaemia meant he was at high risk of cardiac arrhythmias and reduced myocardial

contractility, making him initially a poor candidate for anaesthesia to definitively resolve his urinary obstruction. He was started on IV 0.9% NaCl, and after a rapid bolus the rate was adjusted to meet his maintenance requirement and keep up with the post obstructive diuresis seen after removal of the obstruction. A 0.5g/kg slow IV dextrose bolus was given to reduce the serum potassium levels in the short term until the excess could be excreted. The urethral obstruction was temporarily relieved via removal of a visible plug from the urethral opening which allowed Terror to empty his bladder.

Several hours later Terror's urethra had reobstructed. His electrolytes were rechecked and his potassium level was now down to 5.0 mmol/L. The decision was made at this point to flush Terror's bladder under general anaesthesia. Anaesthesia was induced with alfaxalone and maintained with isoflurane. The obstruction was retropulsed into the bladder, an indwelling catheter was placed and the bladder was flushed copiously. Bladder ultrasound confirmed that

FELINE LOWER URINARY OBSTRUCTION

no large stones were present. Terror recovered well from anaesthesia and remained in hospital overnight on IV fluids, transdermal fentanyl pain relief and urethral relaxants.

The next morning a VetScan critical care panel was run. This showed Terror's azotemia had resolved and electrolytes were all within normal limits. His PCV and TP were also within normal. His IV fluids were changed to a maintenance fluid type (0.45% NaCl in 2.5% glucose with added K+) and the rate was weaned as the post obstructive diuresis resolved. His urinary catheter was removed. Several days later he was urinating well and went home on pain relief, urethral relaxants and struvite prevention diet, and has continued to do well since.

Fig 3. Day 2 lab results

Test Type	Units	Result	Normal Range	H/L
ALT	U/L	55	(20-100)	
GLU	mmol/L	6.5	(3.9-8.3)	
BUN	mmol/L	7.3	(3.6-10.7)	
CRE	μ mol/L	107	(27-186)	
Na+	mmol/L	147	(142-168)	
K+	mmol/L	4.1	(3.7-5.8)	
Cl-	mmol/L	109	(112-126)	L
tCO2	mmol/L	24	(15-24)	
PCV	%	41	(26-45)	
TP	g/L	69	(54-82)	

Summary

Our Abaxis in-house laboratory was critical in the management of this case. Without it, the biochemistry and electrolyte abnormalities would not have been identified and managed as quickly as they were. This equipment was also important in ensuring the hyperkalaemia had resolved prior to anaesthesia; and assisted in decisions regarding fluid type, rate and electrolyte supplementation. The outcome of this case may have been very different if this information had not been available to us so rapidly. Patient side diagnostics were critical in this case.

